

# Homeopathy - A Safe, Much Less Expensive, Non-Invasive, Viable Alternative for the Treatment of Patients Suffering from Loss of Lumbar Lordosis

Saiful Haque<sup>1</sup>, Debarshi Das<sup>1,2</sup>, Saugato Bhattacharya<sup>1</sup>, Tathagato Sarkar<sup>1</sup>, Anisur Rahman Khuda-Bukhsh<sup>1,3\*</sup>

<sup>1</sup>Khuda-Bukhsh Homeopathic Benevolent Foundation, B-2/325, Husn Ara Manzil, Kalyani, India

<sup>2</sup>Bengal Homeopathic Medical College and Hospital, Asansol, India

<sup>3</sup>Retired Professor and Professor Emeritus of University Grant Commission, University of Kalyani, Kalyani, India

## Key Words

bilateral neural foramina, disc desiccation and protrusion, loss of lumbar lordosis, osteophytic lippings, narrowing of secondary spinal canal

## Abstract

**Objectives:** Loss of lumbar lordosis causing pain and curvature of the vertebral skeleton to one side is a relatively uncommon disease. To our knowledge, successful treatment of loss of lumbar lordosis with any potentized homeopathic drug diluted above Avogadro's limit (that is, above a potency of 12C) has not been documented so far. In this communication, we intend to document a relatively rare case of loss of lumbar lordosis with osteophytic lippings, disc desiccation, and protrusion, causing a narrowing of secondary spinal canal and a bilateral neural foramina, leading to vertebral column curvature with acute pain in an adolescent boy.

**Methods:** The patient had undergone treatment with orthodox Western medicines, but did not get any relief from, or cure of, the ailment; finally, surgery was recommended. The patient's family brought the patient to the Khuda-Bukhsh Homeopathic Benevolent Foundation where a charitable clinic is run every Friday with the active participation of four qualified homeopathic

doctors. A holistic method of homeopathic treatment was adopted by taking into consideration all symptoms and selecting the proper remedy by consulting the homeopathic repertory, mainly of Kent.


**Results:** The symptoms were effectively treated with different potencies of a single homeopathic drug, Calcarea phos. X-ray and magnetic resonance imaging (MRI) supported recovery and a change in the skeletal curvature that was accompanied by removal of pain and other acute symptoms of the ailment.

**Conclusion:** Homeopathy can be a safe, much less expensive, non-invasive, and viable alternative for the treatment of such cases.

## 1. Introduction

In the homeopathic mode of treatment, micro doses of ultra-highly-diluted remedies are often used [1] with great benefits to the patient. Some such homeopathic remedies have been reported earlier by us to show their beneficial effects in ameliorating/removing disease symptoms of patients bearing ovarian cysts [2-6], including their successful removal, but no such documentation on any potentized homeopathic drug having shown the ability of ameliorating/curing the symptoms of loss of lordosis seems to exist. In this communication, therefore, we intend to record a case

Received: Sep 28, 2016 Reviewed: Nov 29, 2016 Accepted: Dec 06, 2016

 This is an Open-Access article distributed under the terms of the Creative Commons Attribution Non-Commercial License (<http://creativecommons.org/licenses/by-nc/4.0/>) which permits unrestricted noncommercial use, distribution, and reproduction in any medium, provided the original work is properly cited.

 This paper meets the requirements of KS X ISO 9706, ISO 9706-1994 and ANSI/NISO Z39.48-1992 (Permanence of Paper).

**\*Corresponding Author**

Anisur Rahman Khuda-Bukhsh. Retired Professor and Former Emeritus Fellow of UGC, Department of Zoology, University of Kalyani, Khuda-Bukhsh Homeopathic Benevolent Foundation, B-2/325, Kalyani, Husn Ara Manzil, Kalyani-741235, W.B., India.  
Tel: +91-25-828768 Fax: Not available.  
E-mail: [prof\\_arkb@yahoo.co.in](mailto:prof_arkb@yahoo.co.in)

where a patient with a rare type of structural deformity causing a change in body curvature and pain due to loss of lordosis was cured by the administration of a homeopathic remedy used in different potencies (grades of homeopathic dilution).

Lordosis refers to the normal inward curvature of the lumbar and the cervical regions of the spine [7]. Normal lordotic curvatures, also known as secondary curvatures, cause a difference in the thickness between the front and the back parts of the intervertebral disc. Though lordosis is relatively rare, it can sometimes occur at puberty, usually not becoming evident until the early or mid-twenties. Lumbar hyperlordosis is a condition that occurs when the lumbar region (lower back) experiences stress or extra weight and is arched to the point of muscle pain or spasms. Common causes for such a condition generally include tight lower-back muscles, excessive visceral fat, and pregnancy. Rickets, a vitamin D deficiency in children, can also lead to manifestations of lumbar lordosis. Younger dancers or sportspersons are more at risk for developing lumbar hyperlordosis because the lumbar fascia and hamstrings tighten when a child starts to experience a growth spurt into adolescence. In such cases, in the treatment with the orthodox or Western method, rather complicated surgery is often advised to correct the curvature back to its normal position and to remove the severe pain resulting from the undue curvature.

## 2. Case Study

A boy aged 16 years visited the clinic on March 28, 2016, with excruciating pain in the lower back and hip region. He showed external curvature of his lower back, which gave him a tilted posture, with signs of loss of lordosis. Before coming to this clinic, he visited the clinics of some renowned orthopaedic/neurologic physicians/surgeons after he had started suffering from a gradual development of an awkward curvature of his waistline sidewise and downward due to loss of lordosis. From November 13, 2015, through March 10, 2016, he took allopathic medicines as advised by the different orthopaedic-/neuro-physicians, but without any apparent amelioration of his suffering and pain. Gradually, he started becoming almost immobilized because of his continuous severe back pain during normal movements of the body. He was finally referred to a renowned hospital in Kolkata, India. As he had already been diagnosed with loss of lordosis at L4-L5 and L5-S1 and with disc desiccation and disc protrusion causing a narrowing of the secondary spinal canal and bilateral neural foramina based on X-ray and magnetic resonance imaging (MRI) reports, he was referred for possible surgical intervention. The guardians of the family, who otherwise belonged to the lower middle class, were unable to arrange for the cost of surgical intervention and further medical treatment. Finally, the patient was brought to our homeopathic foundation clinic by his family members on a van rickshaw; he was lying in a peculiar posture with the help of strategic pillow support.

On examination, the following guiding symptoms were recorded:

1. Mind-anger, irascibility, anxiety, irritability, quarrelsome, prostration of mind from talking, ailments from grief;
2. Numbness aggravated in the morning and on waking;
3. Tingling, prickling pain in the lower limbs and hip and in the gluteal muscles of the leg and foot, with the pain being wandering and shifting in nature and being worse in the morning and the evening and changing with the weather and motion;
4. Pain in lower limbs, bones, joints, as well as sciatica-like pain in the lower limbs;
5. Back cramp-like spasmodic pains;
6. Lumbar spine sensitivity;
7. A desire to eat meat;
8. Symptoms being aggravated by cold air in general.

The patient's father agreed to sign the "Informed Consent" form that was read before him. After recording the case history, the most suitable homeopathic remedy and the potency were selected. The selection of the homeopathic remedies was made in consultation with the repertories of Kent [8, 9], and the best remedy indicated for him was *Calcarea phos*. The treatment was started with the 30C potency of *Calcarea phosphoricum* (Calc phos 30C), diluted as per homeopathic dilution procedure  $10^{-60}$  times.

The gradual progress in the straightening of the gait of the patient after administration of the drug is shown in the photographs of the patient in Fig. 1, which are arranged in order from the beginning of drug administration through recovery and discontinuation of the drug; the X-ray images and MRI results are presented in Fig. 2 (before drug administration) and Fig. 3 (after completion of treatment). The course of treatment is as follows:

On March 28, 2016, Calc phos 30C was prescribed thrice a day for 10 days; the patient was advised to visit after 15 days. The patient was considerably bent sidewise and a little downward at the waist line.

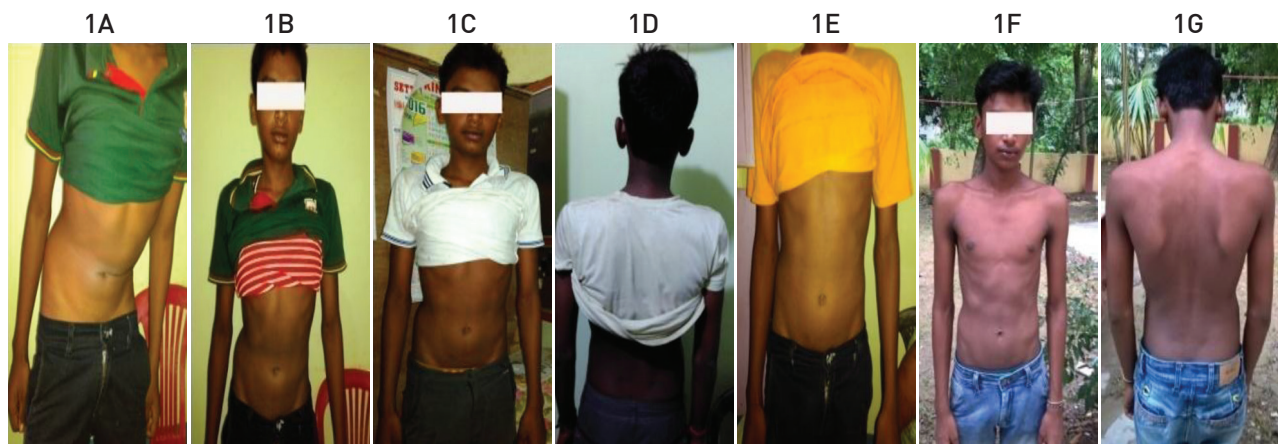On April 14, 2016, Calc phos 30C was prescribed twice daily for 7 days. The patient's pain had been relieved to a considerable extent. He was advised to return in two weeks.

On April 28, 2016, Calc phos 200C was prescribed twice daily for 2 days because he had reported the re-appearance of pain and discomfort. He was advised to visit after 15 days. The curvature was also found to be slightly less on this day.

On May 12, 2016, Calc phos 1000C was prescribed once in the morning on an empty stomach for two consecutive days. At this visit, he reported that at first, the pain had been alleviated quite remarkably and that he had remained well, but the pain had re-appeared with much less intensity. Signs of lumbar straightening were noted. The patient showed encouraging favorable changes in his standing posture, indicating clear signs of a straightening of the curvature.

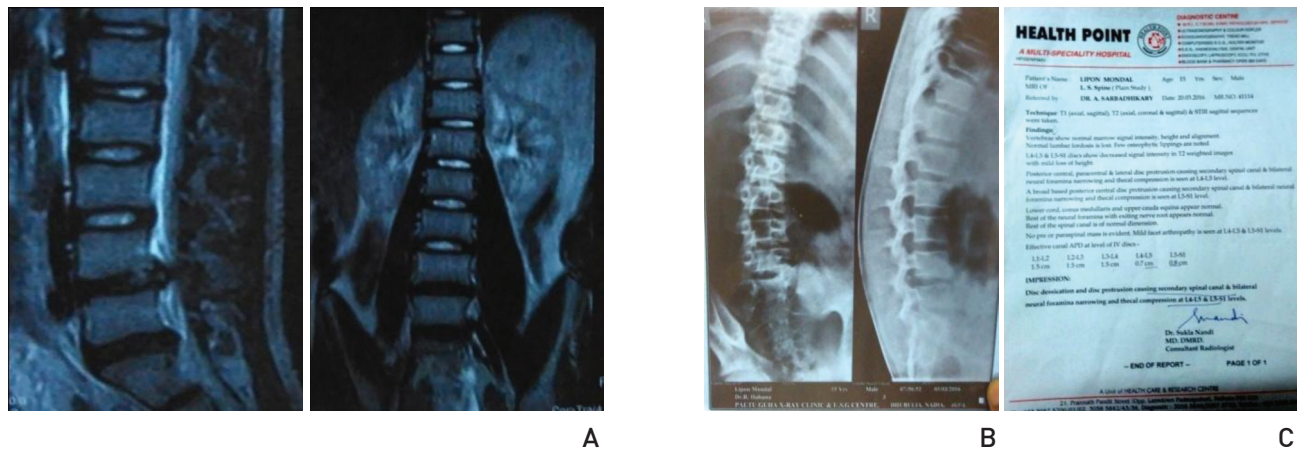
On May 21, 2016, the patient was doing well and reported no pain in movement. The curvature had further straightened; the vertebral column had straightened and considerable mobility had been restored. The patient was advised to undergo an X-ray of the Lumbar-Sacral regions of the spine.

On May 23, 2016, the report for an X-ray on May 22 re-



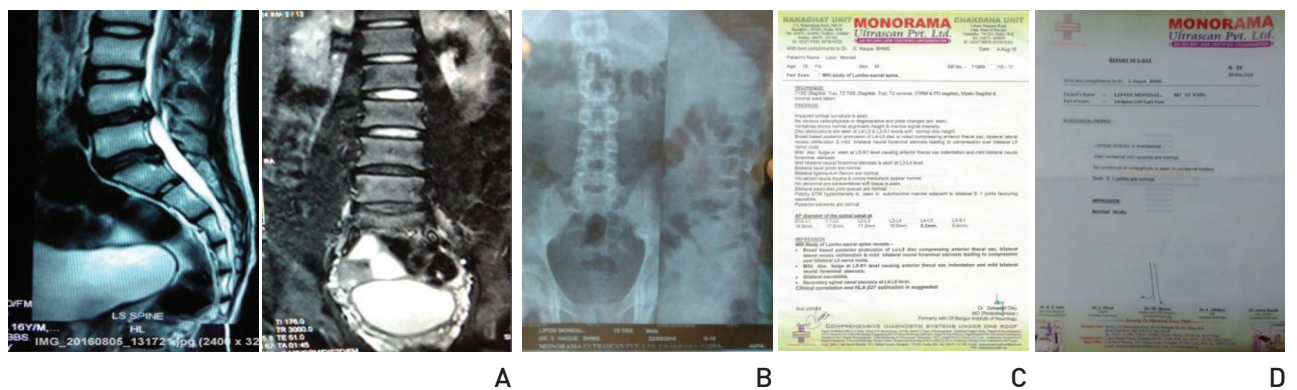
**Figure 1** Gradual improvement of patient's posture and gait are shown.

1A, Before treatment; 1B-1E, Treatment continuing; 1F-1G, After treatment.



**Figure 2** MRI and X-Ray findings before administration of homeopathic medicine.

MRI, magnetic resonance imaging. Before administration of homeopathic medicine: A, MRI of LS Spine; B, X-Ray of LS Spine; C, Report of MRI.



**Figure 3** MRI and X-Ray findings after administration of homeopathic medicine.

MRI, magnetic resonance imaging. After administration of homeopathic medicine: A, MRI of LS Spine; B, X-Ray of LS Spine; C, Report of MRI; D, Report of X-Ray of LS Spine.



vealed that lumbar lordosis was now maintained. Inter-vertebral disc spaces were normal, and no evidence of osteophyte protrusion was seen in vertebral bodies; both S.I. joints were normal. The patient's gait looked quite normal, and he had resumed his normal daily activities. His height was also slightly increased because of the straightening of the spine. He was given a placebo for medication, and he was advised to return after one month.

On June 23, 2016, the patient was doing well and had no problems in movement; he could now ride bicycle. He was advised to undergo an MRI test of the Lumbar-Sacral regions of the spine.

On August 3, 2016, the MRI report revealed remarkable amelioration of the loss of lordosis and favorable changes. A few salient findings were as follows: i) No obvious osteophytic or degenerative end plate changes were found. ii) Vertebrae showed normal alignment, height and marrow signal intensity. iii) Now, only mild bilateral neural foraminal stenosis was seen at the L3-L4 level. iv) Bilateral facet joints and ligamentum flavum were normal; visualized cauda equine and conus medullaris appeared to be normal. v) No abnormal soft tissue was seen. vi) Bilateral sacro-iliac joint spaces were normal. vi) Posterior elements were normal. However, the lumbar curvature was only stated to be "impaired", and the disc bulges seen at the L3-L4 and the L5-S1 levels showed only minor bilateral neural foraminal stenosis. Further the spinal cord at all segments of the inter-vertebral regions showed a much improved AP diameter, indicating vast improvement over before. The patient was prescribed only a placebo and was advised to visit the clinic if he ever again experienced any discomfort or return of any of the symptoms.

### 3. Discussion

Taking into consideration the symptoms in totality, we, after consultation with the Repertory of Kent [8, 9], selected Calc phos at a potency of 30C, which was to be administered in repeated doses. The boy apparently started responding suitably after receiving the remedy for about 10 days, but then the subsided pains re-emerged, necessitating the introduction of a higher potency of 200C as per homeopathic principles. The boy again started to recover in all respects, including the first sign of a straightening of the curvature and a sense of rapid recovery as his pains had again subsided. In addition, his symptom of excessive thirst had been reduced to a great extent; his sweating was also diminished. However, after a few days, his pain re-appeared, but at a much reduced intensity. These observations indicated the need for an even higher potency of Calc Phos, 1000C. The results using this potency were very inspiring. He rapidly improved further to the point where he no longer needed medication. His X-ray report was also very encouraging and corresponded well with the lessening of his external symptoms. In all, the condition of this patient, who had earlier been advised to undergo surgery as treatment for his condition, had been perfectly controlled, and his symptoms had been ameliorated to the extent that he no longer needed surgery.

This case report shows that ultra-highly-diluted po-

tentized homeopathic remedies, if selected properly, can work wonders in rendering relief to patients suffering from difficult physiological conditions such as the one discussed in this report. Furthermore, the study clearly demonstrates that the homeopathic remedy used in this case can provide a viable alternative to surgery for all patients suffering from this rather rare disease, not to mention being of particular help in providing affordable healthcare to the less fortunate persons of society.

### Conflict of interest

The authors declare that there are no conflicts of interest.

### References

1. Hahnemann CFS. Organon of medicine. New Delhi: Jain Publishers Ltd; 1994. p. 31-154.
2. Das D, Das I, Das J, Kayal SK, Khuda-Bukhsh AR. Efficacy of two traditionally used potentized homeopathic medicines, calcarea carbonica and lycopodium clavatum, used for treating PCOS patients: I. effects on certain important external guiding symptoms. Tang Humanitas Medicine. 2016;6(1):31-6.
3. Das D, Das I, Das J, Koyal SK, Khuda-Bukhsh AR. Efficacy of two commonly used potentized homeopathic drugs, Calcarea carbonica and Lycopodium clavatum, used for treating polycystic ovarian syndrome (PCOS) patients: II. Modulating effects on certain associated hormonal levels. Tang Humanitas Medicine. 2016;6(1):7.1-7.7.
4. Das D, Khuda-Bukhsh AR. A patient with uterine fundal leiomyoma and a large hemorrhagic cyst in right ovary cured by homeopathic remedies- a case report. Indian J Med Case Rep. 2016;5(1):13-9.
5. Das D, Samadder A, Kayal KS, Khuda-Bukhsh AR. Removal of large sized ovarian cysts by potentized homeopathic remedies: a myth or a dependable alternative option. IJCAM. 2016;3(5):00088.
6. Das D, Haque S, Samadder A, Kayal KS, Khuda-Bukhsh AR. Removal of large sized ovarian cysts in three patients by administration of a single remedy, *Thuja occidentalis*: hormonal assay and ultrasonographic images. J Integrative Med Ther. 2016;3(1):9.
7. Moore AJ, Newell DW. Tumor neurosurgery: principles and practice. London: Springer-Verlag London; 2006. p. 3-341.
8. Kent JT. Kent's repertory. Calcutta: Sett Dey & Co; 1983.
9. Homopath neometal.1.0 [internet]. Available from: <https://homopath.com/NeoMetal>, MindTechnologies, Mumbai-400054.